

Thick Skin Nose, Rhinoplasty

AHMED M. ALBARAH, M.D.

The Department of Plastic and Reconstructive Surgery, Faculty of Medicine, Menoufiya University

ABSTRACT

Background: The nasal skin quality is one of the most significant factors that affect the final aesthetic result. The thick skin is usually accompanied by a thick subcutaneous layer. Both are less elastic and contract less than thin skin; this leads to soft tissue pollypeak deformity, excessive supra tip scarring, and long standing postoperative edema.

Aim of the Study: Is to evaluate the results of rhinoplasty for thick skin nose patients and discuss the techniques that can improve these results.

Patients and Methods: (20) patients (16 women and 4 men) ranged in age between 16 to 42 years asked for aesthetic rhinoplasty. All patients had thick skin nose in association with other deformities. Open approach was used for all. Columellar strut, suturing techniques and many types of cartilage grating were used to get more support and definition of the nasal tip.

Results: After an average follow-up period of 8 months, 16 patients were satisfied by their results and four cases accepted the results but commented that they will be better with more projection and tip definition. No one of them asked for secondary rhinoplasty.

Conclusion: Thick skin nose is not a contraindication for rhinoplasty but it needs special consideration in its management. Especially for thick skin nose it is important to have good selection for your patient. For these patients, it is better to get a large well supported nose that is in harmony and balance with the face than small imbalanced and weakly supported one. Strong Columellar strut, suturing techniques and many types of cartilage grafting are mandatory to have well supported nose and definition of the tip.

INTRODUCTION

Rhinoplasty, one of the most frequently performed cosmetic surgical procedures, has been the most interesting field among plastic surgeons for many years [1]. The evaluation of rhinoplasty patient should take into account the skin and soft tissue covering of the nose as the final result will be significantly influenced by the thickness, texture and sebaceous nature of the skin [2,3].

Sebaceous glands are more numerous in the caudal half of the nasal skin. This is especially true in the non-Caucasian nose, which commonly

displays a greater amount of subcutaneous fibrous fatty tissue. This dense layer of tissue often measuring as much as 6 mm thick obscures the contour of the underlying alar cartilages in the non-Caucasian nose [4].

The thick skin is usually accompanied by a thick subcutaneous layer. Both are less elastic and contract less than thin skin; this leads to soft tissue pollypeak deformity, excessive supra tip scarring and long standing postoperative edema [5].

Thick sebaceous skin tends to be inelastic, possessing a memory of its own. A nose with thick skin may suggest the temptation for aggressive change in the shape of underlying cartilage to effect a change in soft tissue nasal contour. These aggressive maneuvers tend to weaken the support of the nasal skeleton, which may ultimately buckle and collapse under the forces of scar contracture [6].

As the thick skin does not confirm the reduced framework, skeletal framework should not be reduced but should be supported in special areas. The more thickened the skin, the more support it requires [7].

PATIENTS AND METHODS

This study was conducted at Menoufiya University Hospital during the period from January 2007 to December 2010. All patients came to our attention at Menoufiya University Hospital seeking for aesthetic rhinoplasties were evaluated by the author.

Twenty patients with thick skin nose in association with other deformities were included in this study. There were 16 women and 4 men, and age ranged from 16 to 42 years.

Exclusion criteria included patients with high expectations, unstable personality, patients with bleeding disorders, those under isotretinoin treatment and those asking for secondary rhinoplasty.

Detailed history of each patient was taken. Complete facial and nasal aesthetic analysis was done and the goals were individualized for each patient. Postoperatively, all patients were followed-up for 6 to 18 months (average 8 months).

Operative technique:

All patients were managed by open approach rhinoplasty under hypotensive general anesthesia with infiltration of the entire external and internal nose by a mixture of 1-2% lidocaine and 1/200000 epinephrine. Single dose of 8 mg dexamethasone was given IV for each patient one hour preoperatively.

Skin dissection was done in the subpericondrial and subperiosteal planes just superficial to the nasal cartilages and bony dorsum up to the root of the nose. This enables skin retraction of the undermined area and exposing the entire nasal framework.

The loose subcutaneous prominent supratip fibrofatty tissue was removed from the under surface of the skin flap "defatting" to thin the tip. It was done very cautiously by the back of scissor without subdermal defatting to avoid ischemia of the columellar flap and nasal tip skin irregularities. Also, the interdomal pad of fat was excised.

The tip cartilages were evaluated as regards its shape, thickness and strength and correlated with the preoperative diagnosis.

The Septal work was performed first to modify the dorsal height; tip rotation, nasal length and columellar show, correct any functional problems and obtain any cartilages necessary for grafting. The septum can be approached from both the superior septal angle and the caudal end.

When indicated, (in 14 cases) the osteotomies were performed first followed by tip modifications. All the lateral osteotomies were done internally without periosteal dissection.

Usually many techniques (excision, transsection, scoring, morselization, suturing and many types of cartilage grafting) were required to modify the tip cartilages. Columellar strut, suturing and tip grafts were used in all cases, spreader graft in 12 cases, onlay dorsal graft in 10 cases and lateral crural graft in 4 cases.

The skin was redraped after a final inspection of the nasal framework. The transcolumellar incision was closed with inverted one or two subcutaneous 6/0 vicryl sutures then by meticulous 6/0 interrupted prolene sutures. Nasal packing was

used in all cases as the septum was manipulated in all cases. Compressive taping of the nose with steri strips was done with special care for the tip followed by plaster of Paris splinting.

When alar base excision was indicated (10 cases), it was postponed one month postoperatively to avoid ischemia of the columellar flap and excessive post operative tip edema. This technique also provides additional tip rotation and projection.

Postoperative care:

Double doses of 8mg dexamethasone were given for each patient during the first 24 hours. Nasal packing was removed 24 hours postoperatively. Nasal splint was left for 7 days while the nasal skin taping was maintained for another one week, after that, night taping was used for three weeks. Hot fomentations, repeated massage and local and systemic anti edematous drugs, all were advised postoperatively. Cautious steroid local injections were used for (14) patients who had supratip deformities despite conservative treatment for more than one month.

RESULTS

After an average follow-up period of 8 months, 16 patients were satisfied by their results, and four cases accepted the results but commented that; they will be better with more tip projection and definition. No one of them asked for secondary rhinoplasty.

We found no instances of complications, such as infection, hematoma, skin necrosis, septal perforation and displacement or absorption of grafted cartilage. Moreover, scars from all the incisions were accepted by the patients.

Case reports:

Case (1):

A 37 year old female patient presented with large and unrefined nose. By examination the nose appeared to have a thick skin with a poorly defined bulbous tip, wide bony base, wide dorsal aesthetic lines, alar flaring and alar columellar disharmony.

Open approach rhinoplasty was used followed by excision of the interdomal fat pad and the subcutaneous fibrofatty tissue, harvesting septal cartilage, cephalic resection of lower lateral cartilages (preserving 6mm of lower lateral cartilage rim), medial and lateral osteotomies, columellar strut, graduated tip suturing techniques using interdomal and transdomal sutures, tip grafting using the combined onlay and infratip grafts (Gunter type). Finally, alar base resection was done one

month postoperatively. The postoperative views demonstrated improved tip definition and projection, more up rotation, better dorsal aesthetic lines and bony base, better columellar show and narrowing of the alar base (Fig. 1).

Case (2):

A 16 year old female patient presented with thick skin poorly defined bulbous tip, wide dorsal aesthetic lines, wide bony base, and alar flaring. By open approach rhinoplasty the following was done: Excision of the interdomal fat pad and subcutaneous fibrofatty tissue, harvesting septal cartilage, cephalic resection of lower lateral cartilages, median and lateral osteotomies, columellar strut, spreader graft, dorsal onlay graft, tip suturing and grafting using combined infratip and onlay grafts. Alar base resection was decided to be done one month postoperatively but the patient refused. Postoperative views demonstrated improved tip

definition, better projection and up rotation of the tip, better dorsal aesthetic lines, narrower bony base and better columellar show (Fig. 2).

Case (3):

A 37 year old female patient had severely thick skin nose, poorly defined tip, wide bony base, wide dorsal aesthetic lines, alar flaring and wide alar base. By open approach rhinoplasty the following was done: Excision of the interdomal fat pad and the subcutaneous fibrofatty tissue, harvesting septal cartilage, cephalic resection of lower lateral cartilages, median and lateral osteotomies, columellar strut, spreader graft, dorsal onlay graft, tip suturing techniques and tip grafting. Alar base resection was done one month postoperatively. Postoperative views demonstrated improved tip definition, better projection and up rotation of the tip, better dorsal aesthetic lines, narrow bony base and better columellar show (Fig. 3).

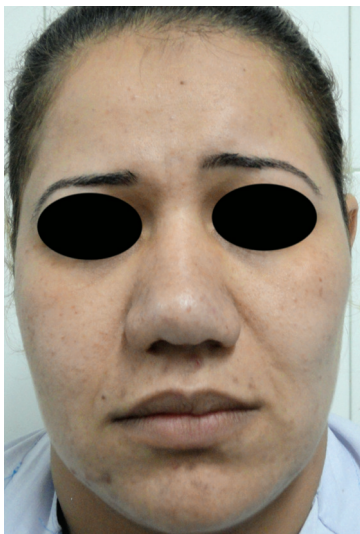

Fig. (1A): Preoperative frontal view.

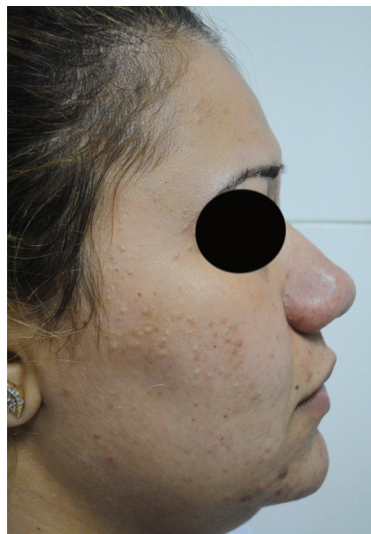


Fig. (1B): Preoperative lateral view.

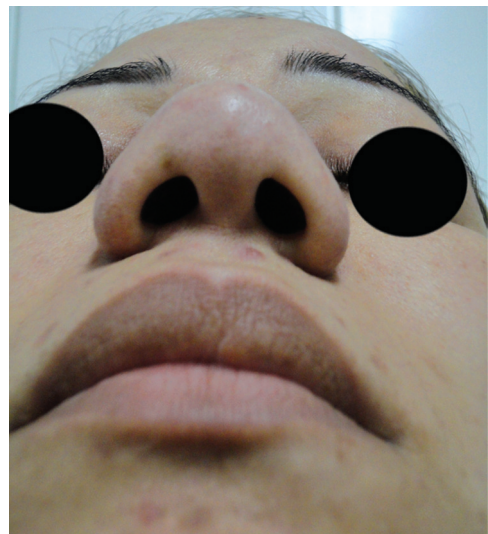

Fig. (1C): Preoperative basal view.

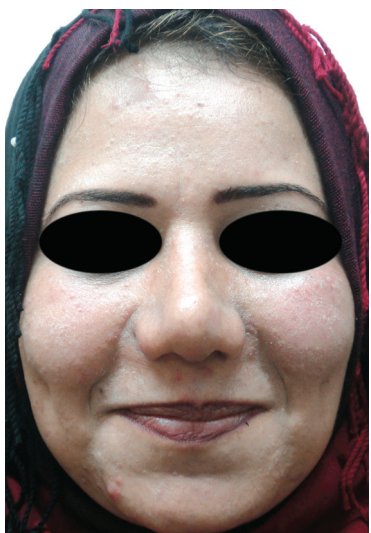

Fig. (1D): Postoperative frontal view.

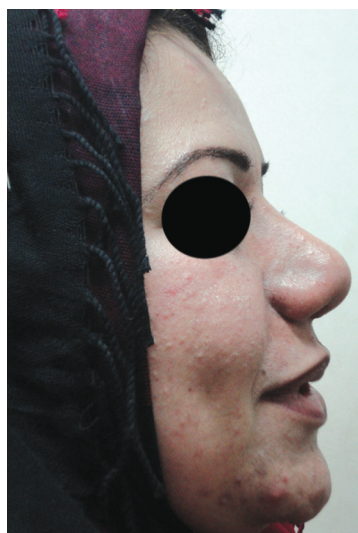

Fig. (1E): Postoperative lateral view.



Fig. (1F): Postoperative basal view.

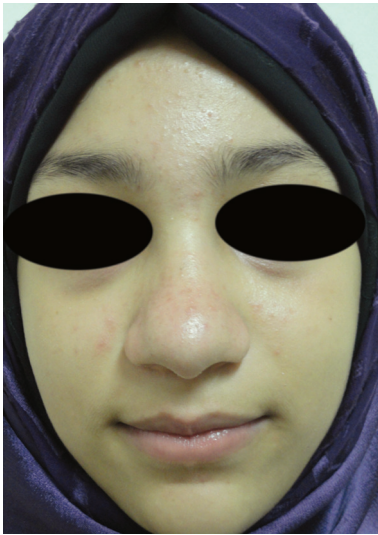

Fig. (2A): Preoperative frontal view.

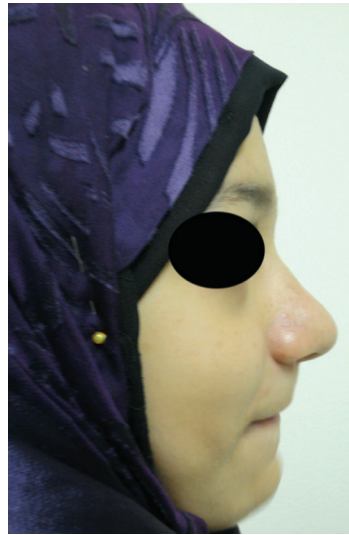

Fig. (2B): Preoperative lateral view.

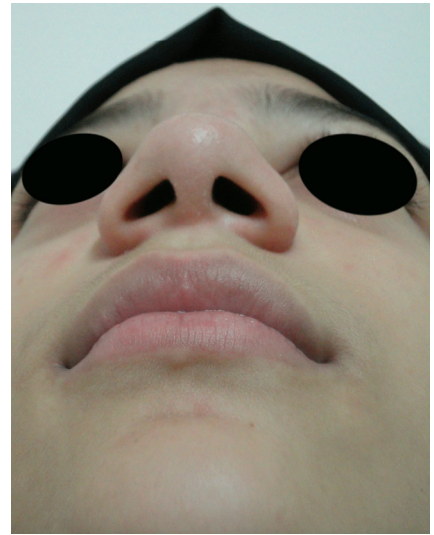

Fig. (2C): Preoperative basal view.

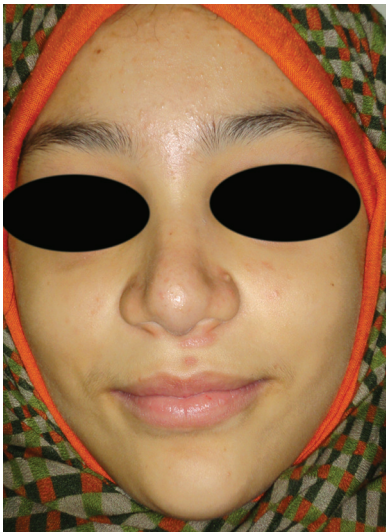

Fig. (2D): Postoperative frontal view.

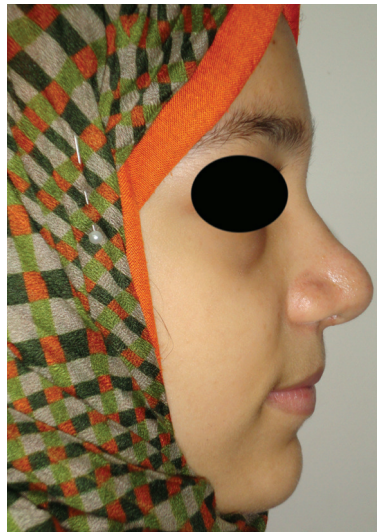

Fig. (2E): Postoperative lateral view.

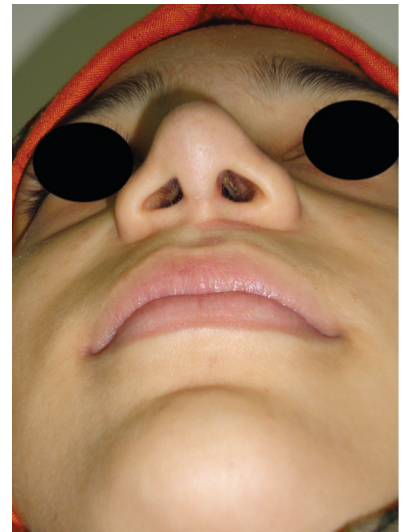


Fig. (2F): Postoperative basal view.

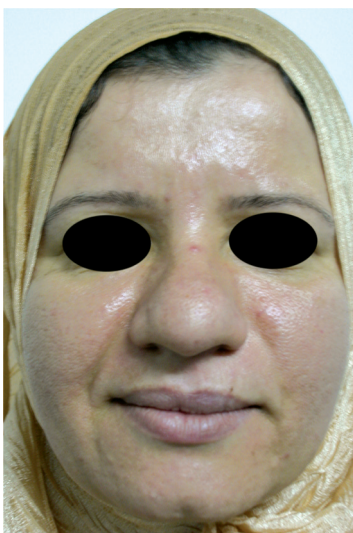

Fig. (3A): Preoperative frontal view.

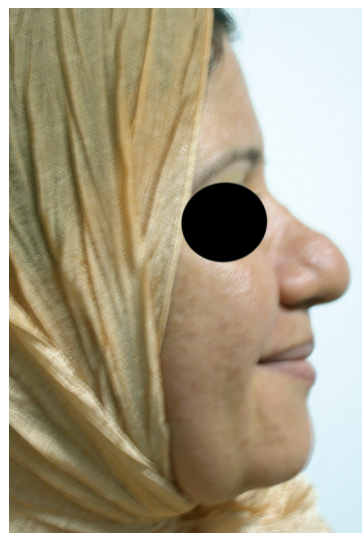

Fig. (3B): Preoperative lateral view.

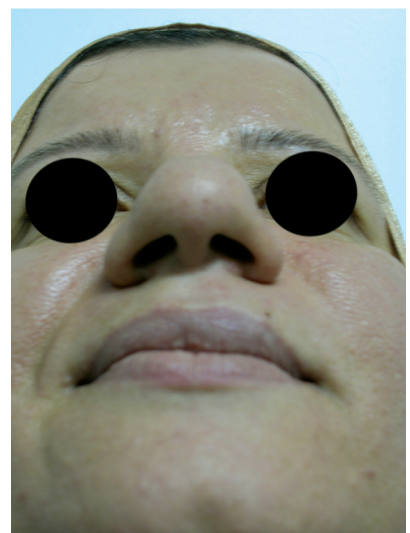

Fig. (3C): Preoperative basal view.

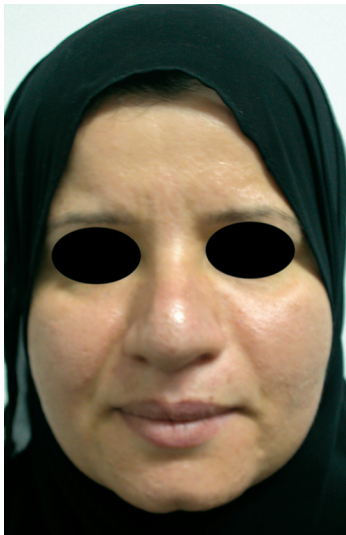

Fig. (3D): Postoperative frontal view.

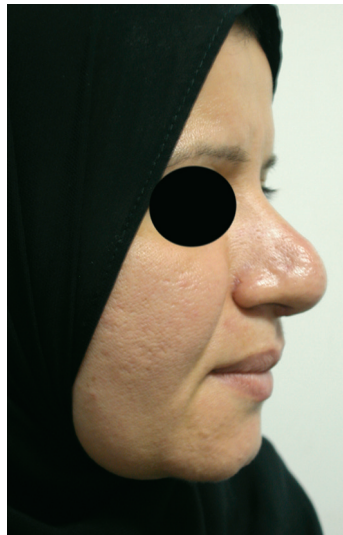

Fig. (3E): Postoperative lateral view.

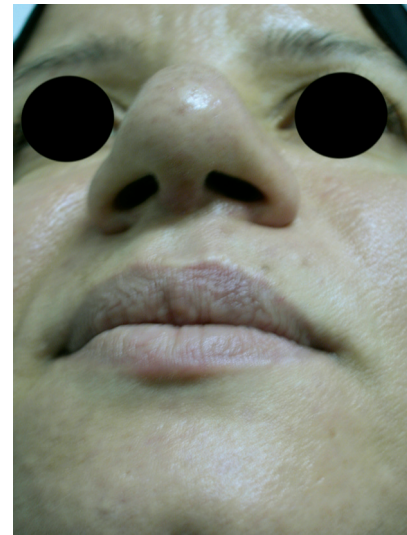


Fig. (3F): Postoperative basal view.

DISCUSSION

Complications of rhinoplasty can be classified into hemorrhagic, infectious, traumatic, functional or aesthetic problems [8]. The thick skin rhinoplasty patient is more prone to certain complications so, in this study, patients with high expectations were excluded. Also, patients with recent history of isotretinoin therapy were excluded as they are more liable to postoperative complications [9].

Although the edema of the nasal tip subsides more quickly if the columella is not transected [10], all our patients were managed by open approach rhinoplasty. Open rhinoplasty is good for diagnosing the cause of deformity as it opens up the bone structure completely which is the key to nasal plastic surgery [11]. Therefore, with open rhinoplasty, direct and accurate correction is possible, and it is easy both to approach the nasal septum and to achieve hemostasis. Also, precise cartilage grafting is more easily achieved by this way [1].

After the nasal skin dissection, excess fibrofatty tissue was removed with preservation of subdermal plexus to avoid postoperative nasal tip necrosis. This maneuver is safe and enhances tip definition by decreasing the thickness of the overlying soft-tissue envelope [12].

Usually the thick skin nose is accompanied by thin and weak cartilaginous framework that gives weak support to the overlying heavy skin and fibrofatty tissue. Iatrogenic loss of tip support may result from purposeful or unintended violation of critical tip-supporting structures [13,14]. The open approach can also lead to diminished tip projection by virtue of disruption of skin and soft-tissue supports [11].

This initially weak support of the nasal tip in thick skin nose patients in addition to its iatrogenic loss or decrease during surgery can be counteracted by tip-suturing techniques and use of supportive strut grafts.

In this study, a cephalic trimming of the lower lateral cartilages was performed in all cases. Although it decreases tip support through disruption of the upper and lower lateral cartilages attachments it is essential to make the supra alar depression, more tip definition and up rotation. At least 6-mm-wide rim strip must be left intact.

The columellar strut graft was used in all cases; it is the key stone reconstructive and aesthetic procedure for thick skin nose as it can strengthen nasal tip support, provide an additional increase in tip projection and up rotation, change the degree of columellar show and refine the infratip columella-lobule region.

Suture reshaping techniques (Interdomal and transdomal) were used in all cases, unlike cartilage scoring or resection, Suture techniques have the distinct advantage of being nondestructive, incremental, and reversible [15]. The historically, conventional destructive and irreversible tip-modification techniques such as cartilaginous resection, transection, morselization, and scoring have been replaced by nondestructive, reversible, incremental, and dynamic tip-suturing techniques [16].

More tip definition was obtained by a combined infratip lobular/onlay tip graft (Gunter-type). For more infralobular definition a Sheen type graft was used. Double or triple-layer onlay cartilage grafts may be additionally required to attain final tip definition and projection [17]. After the final

tip projection was established dorsal onlay grafts were used in 10 cases for dorsal augmentation.

Guyuron et al. [18] used the steri strip taping for management of early postoperative edema and supratip deformities. In this study, nasal skin taping with steri strips was used for two weeks followed by night taping for another two weeks. This taping is considered as a prophylactic garment to avoid postoperative edema.

Repeated injection (1 to 3 times with one month interval) of a small amount of triamcinolone acetonide (0.2 to 0.4cc of 20mg/cc) was used for 14 patients. This technique was described by many authors to treat long standing postoperative edema and supratip deformity persistence [19,20]. The steroid solution should be injected into the deepest portion of the soft tissue and intradermal injection should be absolutely avoided [21].

Although columellar flap necrosis has been reported after open rhinoplasty, [22] and the risk of ischemia is theoretically higher with simultaneous alar base excision, [23] it is used by many rhinoplasty surgeons. In this study, alar base excision was performed for 10 cases one month post-operatively as outpatient procedure with local anesthesia. We preferred that to avoid ischemia of the columellar flap and excessive post operative tip edema.

Conclusion:

Thick skin nose is not a contraindication for rhinoplasty but it needs special consideration in its management. Especially for thick skin nose it is important to have good selection for your patient. For these patients it is better to have a large well supported nose that is in harmony with the face than small weakly supported one. Strong Columellar strut, suturing techniques and cartilage grafting are mandatory to have well supported nose and definition of the nasal tip.

REFERENCES

- 1- Lee C.H., Kwon S.Y., Park M.J., Kim K.S., Park H.S. and Kim H.J.: Nasal Tip Plasty Using Various Techniques in Rhinoplasty. *Aesth. Plast. Surg.*, 28: 445-455, 2004.
- 2- Orent S.S. and Hilger P.A.: Facial Analysis of the Rhinoplasty Patient, in *Facial plastic and reconstructive surgery*. 2nd edition, Vol. I, Chapter 31, pp 361-362, Thieme medical publishers, New York, 2002.
- 3- Gunter J., Rohrich R., Adams W., eds.: *Dallas Rhinoplasty*, 2nd edn, Vol. II. St. Louis MO: Quality medical Publishing, 2007.
- 4- Zingaro E.A. and Falces E.: Aesthetic anatomy of the non-Caucasian nose. *Plast. Surg. Clin.*, 14: 749, 1987.
- 5- Peck G.C. and Michelson L.N.: Anatomy of aesthetic surgery of the nose. *Facial aesthetic surgery clinics in Plastic Sargery*, Vol. 14, No. 4, 1987.
- 6- Tardy M.E., Kron T.K., Younger R., et al.: The cartilaginous pollybeak: Etiology, prevention and treatment. *Fac. Plast. Surg.*, 6: 2, 1989.
- 7- Fethi O., Akin Y. and Yagmur A.: A new extrasupported tip graft in the treatment of bulbous nasal tip. *Aesth. Plast. Surg.*, 22: 259, 1998.
- 8- Cochran C.S. and Landecker A.: Prevention and Management of Rhinoplasty Complications. *Plast. Reconstr. Surg.*, 122 (2): 60e, 2008.
- 9- Allen B.C. and Rhee J.S.: Complications Associated with Isotretinoin Use after Rhinoplasty. *Aesth. Plast. Surg.* 29: 102-106, 2005.
- 10- McKinney P.: Management of the bulbous nose. *Plast. Reconstr. Surg.*, 106: 906, 2000.
- 11- Gunter J.P. and Rohrich R.J.: External approach for secondary rhinoplasty. *Plast. Reconstr. Surg.*, 80: 161, 1987.
- 12- Rohrich R.J. and Muzaffar A.R.M.: Rhinoplasty in the African-American Patient. *Plast. Reconstr. Surg.*, 111 (3): 1322, 2003.
- 13- Rich J.S., Friedman W.H. and Pearlman S.J.: The effects of lower lateral cartilage excision on nasal tip projection. *Arch. Otolaryngol. Head Neck Surg.*, 117: 56, 1991.
- 14- Petroff M.A., McCollough E.G., Hom D. and Anderson J.R.: Nasal tip projection. *Arch. Otolaryngol. Head Neck Surg.*, 117: 783, 1991.
- 15- Rohrich W.J. and Adams W.P.: The Boxy Nasal Tip: Classification and Management Based on Alar Cartilage Suturing Techniques. *Plast. Reconstr. Surg.*, 10: 1849, 2001.
- 16- Ghavami A., Janis J.E., Acikel C. and Rohrich R.J.: Tip Shaping in Primary Rhinoplasty: An Algorithmic Approach., 122 (4): 1229, 2008.
- 17- Rohrich R.J.: Graduated approach to tip projection in rhinoplasty. Presented at the 14th Annual Dallas Rhinoplasty Symposium, Dallas, Texas, March 1997.
- 18- Guyuron B., DeLuca L. and Lash R.: Supratip Deformity: A Closer Look, *Plast. Reconstr. Surg.*, 105: 1140, 2000.
- 19- Copcu E., Metin K., Culhaci N. and Ozkok S.: The New Anatomical Viewpoint of the Nose: The Interdomal Fat Pad. *Aesth. Plast. Surg.*, 27: 116, 2003.
- 20- Foda H.M.T.: Exteral rhinoplasty: A critical evaluation of 500 Cases. *J. laryngol. Otol.*, 117: 473, 2003.
- 21- Hanasono M.M., Kridel R.W., Pastorek N.J., Glasgold M.J. and Koch R.J.: Correction of the soft tissue pollybeak using triamcinolone injection. *Arch. Facial Plast. Surg.*, 4: 26, 2002.
- 22- Burgess L.P.A., Everton D.M., Quilligan J.J., et al.: Complications of the external (combination) rhinoplasty approach. *Arch. Otolaryngol. Head Neck Surg.*, 112: 1064, 1986.
- 23- Bafaqeeh S.A. and Al-Qattan A.A.: Simultaneous Open Rhinoplasty and Alar Base Excision: Is There a Problem with the Blood Supply of the Nasal Tip and Columellar Skin? *Plast. Reconstr. Surg.*, 105: 344, 2000.